

# CHEST RADIOGRAPHIC FINDINGS IN CHILDREN WITH ASPIRATION PNEUMONIA (CASE REPORT)

*Darejan G. Sturua<sup>1</sup>, Nino J. Jojua<sup>2</sup>, Tamar T. Dundua<sup>3</sup>*

## ABSTRACT

Aspiration pneumonia is an important cause of morbidity in pediatric patients, particularly in high-risk groups such as premature infants and children with neurological disorders, dysphagia, or gastroesophageal reflux disease. Impairment of normal protective mechanisms increases the risk of aspiration, while Mendelson's syndrome represents a severe form of gastric acid-induced lung injury. Radiologically, aspiration pneumonia typically presents with an initial alveolar pattern that may progress to interstitial involvement. Common imaging findings include perihilar infiltrates, consolidation, and atelectasis, most frequently affecting the right lower lobe. In mild cases, radiographic changes may resolve within 24–48 hours, whereas acidic aspiration may result in more significant pulmonary injury. Chest radiography remains the primary diagnostic tool. Early diagnosis and management are essential to prevent complications and chronic lung damage. This study presents pediatric case of aspiration pneumonia and its radiological findings.

Pneumonia is a common and potentially serious respiratory infection that affects the lungs, especially affecting the pulmonary alveoli where the terminal branches of the bronchi and interstices flow. It can be caused by various microorganisms, including bacteria, viruses, fungi, and even certain chemicals, resulting in inflammation and swelling of the air sacs in one or both lungs [19]. Aspiration pneumonia (AP) generally is characterized by inflammation of lung parenchyma after aspiration of

<sup>1</sup> M. Iashvili Central Children's Hospital; D.Tvildiani Higher Medical School Ayet, Tbilisi, Georgia; <sup>2</sup> M. Iashvili Central Children's Hospital, Tbilisi, Georgia; <sup>3</sup>University of Georgia; Clinic Cortex, Tbilisi, Georgia

**Keywords:** Aspiration pneumonia, Chest radiography, Radiology, Diagnosis in children

Cite: Sturua D.G., Jojua N.J., Dundua T.T. Chest radiographic findings in children with aspiration pneumonia (cases report). *Cauc J Med & Psychol Sci.* 2025; V.3 (№ 3-4): 63-71 ; DOI 10.61699/cjmps-v3-i3-4-p63-71

oropharyngeal or upper gastro intestinal contents in large volumes. The material that can be aspirated varies and includes saliva, liquids, nasopharyngeal secretions, bacteria, toxic substances, food, or gastric contents [6; 22]. Aspiration Pneumonia has a significant impact on individuals of all age groups, which can result in morbidity and a substantial reduction in the quality of life [18]. Generally, it occurs in elderly, debilitated patients with dysphagia. The incidence of pneumonia and pneumonia mortality are both greater in the elderly population, and as human life expectancy continues to increase, it is anticipated that pneumonia deaths will also increase [10]. The most common type of pneumonia in the elderly is aspiration pneumonia [12]. R. P. Shabeera & V. Mounika (2024) suggest a change in nomenclature: they propose the term Frailty-Associated Pneumonia for pneumonia in older, frail adults [19]. Paediatric populations have different causes of dysphagia than adult populations. These causes include: cerebral palsy; acquired/traumatic brain injury; other neuromuscular disorders; craniofacial malformations; airway malformations; congenital cardiac disease; gastrointestinal disease; ingestional injuries; and preterm birth. [19]. Altered consciousness refers to children with seizures, cerebrovascular accidents, head trauma, drug overdose, meningitis, encephalitis or under general anesthesia. Anatomic disorders include cleft palate, anomalies of face and skull, neoplasms, diverticulae, tracheo-esophageal fistula and scleroderma [9; 14]. Physiologic disorders are an incompetent cardiac sphincter, gastric outlet obstruction, gastro-esophageal

reflux disease and vomiting. Neurologic disorders include Down syndrome, Werdnig-Hoffman disease, myasthenia gravis, birth asphyxia, cerebral palsy and preterm birth. Mechanical disruption of normal defence barriers refers to patients with instrumentation such as nasogastric tube, endo-tracheal intubation or tracheostomy [9]. Accidental aspiration includes drowning as well as the ingestion of materials like kerosene, peanuts and betel nuts [1]. Aspiration pneumonia represents 5% to 15 % of pneumonias in the hospitalized population [19]. The mortality rate for AP is more than twice that of other pneumonias [11]. Aspiration pneumonia was identified as the most important contributor to deaths among all pneumonia etiologies investigated [2]. According to J.G. Bartlett (1993), for aspiration pneumonia to occur, there must be a breakdown of the usual defences that normally protect the tracheobronchial tree, as well as pulmonary complications that result from the aspiration event. Conditions predisposing to the development of pulmonary aspiration include altered consciousness, anatomic disorders, physiologic disorders, neurologic disorders, mechanical disruption of the normal defence barriers and accidental ingestion of substances [1; 9]. While some researchers report that the incidence of aspiration syndromes associated to anatomical or neurological disorders is unknown [5]. Aspiration pneumonia has significant clinical importance in pediatric patients in terms of the morbidity and mortality associated with it [9]. It is a frequent cause of morbidity and mortality in children with neurological deficits [23;

24; 5; 12]. In patients with predisposing diseases, prompt diagnosis of this complication and correct preventive measures can drastically reduce the worsening of clinical conditions and deaths due to aspiration pneumonia [15].

Under normal physiological conditions, the respiratory tract is protected from aspiration by several mechanisms, including the cough reflex, coordination of swallowing, closure of the epiglottis during swallowing, and mucociliary clearance of the airways [3, 21]. Dysfunction or immaturity of these protective mechanisms significantly increases the risk of aspiration and the subsequent development of infection. In children, aspiration can be caused by immaturity of swallowing coordination, neurological disorders, developmental anomalies, gastroesophageal reflux disease, or congenital abnormalities such as tracheoesophageal fistula [8, 2]. Premature infants with low birth weight, as well as children with dysphagia or central nervous system disorders, seizure disorders and esophageal abnormalities represent a particularly high-risk group [8, 2, 4].

Mendelson's syndrome represents a well-recognized form of chemical pneumonitis following gastric content aspiration [7, 20]. Small aspiration episodes may also occur in healthy individuals, however, pneumonia develops only when the aspirated material contains pathogenic microorganisms or when the body's defense mechanisms are compromised [21].

Radiologically, aspiration pneumonia

typically presents with an initial alveolar pattern, reflecting airspace consolidation. Transition to an interstitial pattern may occur as macrophages respond to and interact with the aspirated material. In chronic cases, the inflammatory process may evolve into a mass-like lesion, potentially mimicking neoplastic pathology. The clinical course may be prolonged, particularly in the presence of aspirated anaerobic gastric flora. In cases of acute aspiration especially involving small volumes of non-infected material, radiographic abnormalities often resolve spontaneously within 24-48 hours. Conversely, aspiration of undiluted gastric acid may manifest as mild, transient pulmonary infiltrates [20].

Chest radiography in children remains the primary method for diagnosing and evaluating aspiration pneumonia. In pediatric patients, the radiological findings depend on the localization of the aspirated material or foreign body and on the patient's position at the moment of aspiration [3, 13]. Typical imaging appearance may include perihilar infiltrates, peribronchial thickening, segmental consolidation and atelectasis [8, 13]. In infants and young children, hyperinflation or mosaic ventilation patterns may also be observed, which are associated with inflammatory processes of the small airways [16, 17]. Aspiration more frequently affects the right lung, particularly the right lower lobe, due to the vertical orientation and wider diameter of the right main bronchus [13, 16]. Early diagnosis and treatment significantly reduce the risk of complications and the development of chronic lung damage [21, 8].

The objective of this study is to characterize the case of aspiration pneumonia in child on the basis of the chest radiographic appearance.

### Case presentation

Patient: 1-year-old female N. CH. presented to the clinic with difficulty breathing, cough, and fever. (Past medical history of the patient was born prematurely at 30 weeks of gestation, via cesarean section, weighing 1270 g, one of twins. She was treated in the NICU with the following diagnoses: Neonatal respiratory distress syndrome; Required mechanical ventilation for approximately 2 weeks after birth; Neonatal respiratory failure; Necrotizing enterocolitis; Gastroesophageal reflux. Notably, according to the history, the patient had recurrent episodes of aspiration during feeding, which preceded the onset of respiratory symptoms.)

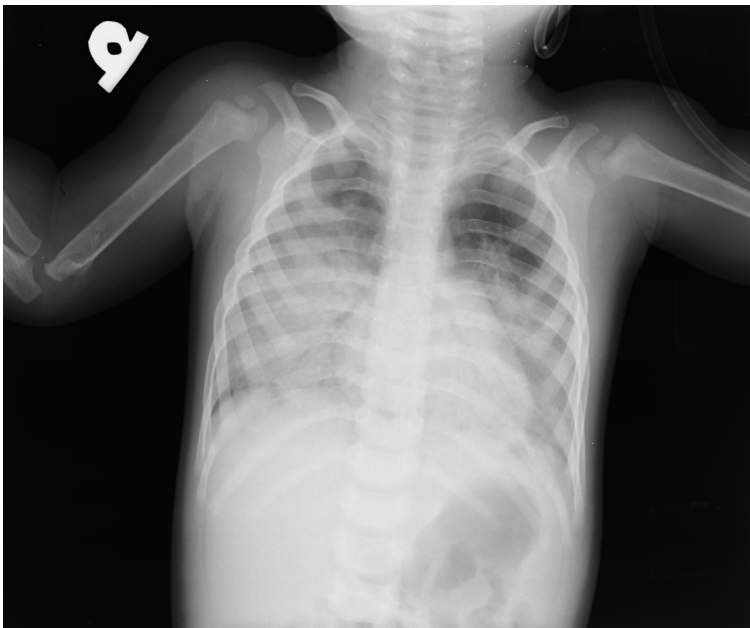

Fig. 1. X-ray was taken during the first hours after the patient's admission to the clinic

Vital Signs on Admission: Respiratory rate: 100/min; Blood pressure: 91/49 mmHg; Temperature: 38°C; Oxygen saturation: 89%; Heart rate: 180/min. Initial Clinical Status: On admission to the ICU (intensive care unit) the patient's general condition was severe due to acute respiratory failure secondary to pneumonia. She was breathing spontaneously, with marked tachypnea, retractions, and use of accessory muscles. Desaturation was noted on room air. Oxygen therapy via mask (8–10 L/min) and inhalation therapy were initiated, but oxygenation remained insufficient. Therefore, non-invasive ventilation (NCPAP) was started, resulting in satisfactory oxygenation. Neurological Status: Developmental delay present, Alternating adynamia and agitation, Pupils equal, round, reactive to light, Dexmedetomidine infusion initiated. General Examination: Skin: pale, mottled, subcutaneous fat moderately developed, Extremities warm Febrile; antipyretics administered with good response. Cardiovascular System: Hemodynamically stable, Tachycardia, Peripheral pulses of moderate filling, slightly muffled heart sounds, Capillary refill: 2.5 sec. Respiratory System: Symmetrical chest excursion, Auscultation: decreased breath sounds on the right with crepitations. Other Findings: Oropharynx: hyperemic; Abdomen: soft, non-tender; Urination and defecation reduced. Laboratory Findings: Leukocytosis; CRP: 53 mg/L; Procalcitonin: 2.45 ng/mL; Other parameters within acceptable limits. Imaging Chest X-ray: Bilateral lower lung infiltrates consistent with aspiration pneumonia. Given the history of aspira-

tion and severe respiratory compromise, bronchoscopy was performed, which revealed inflammatory secretions within the bronchial tree. Bronchial toileting was carried out contributing to airway clearance. The next day the patient's condition worsened despite appropriate treatment. She was intubated under sedation and placed on mechanical ventilation (SIMV mode) with high settings. One week later, the patient's clinical condition gradually improved. Follow-up chest X-ray: partial improvement, especially in the left lung. The patient was extubated successfully. After a few days, the patient was discharged home with the stable condition and recommendations.

Infiltrative areas are present in the bilateral lower lung fields, with signs of air bronchograms (Fig.1). Infiltrative areas are present in the bilateral lower lung fields, with signs of air bronchograms. (The patient was intubated) (Fig.2). Infiltrative areas reduced in both lungs (Fig.3). The lung fields are clear, with persistent prominent vascular markings on the right (Fig. 4).

### Conclusion

Aspiration pneumonia remains an important cause of respiratory complications, particularly in children with neurological impairment, prematurity, or gastroesophageal reflux. Early recognition, appropriate clinical management, and radiological assessment play a crucial role in diagnosis and monitoring the disease course. Timely treatment may lead to favorable clinical outcomes, although radiographic changes can persist for some time

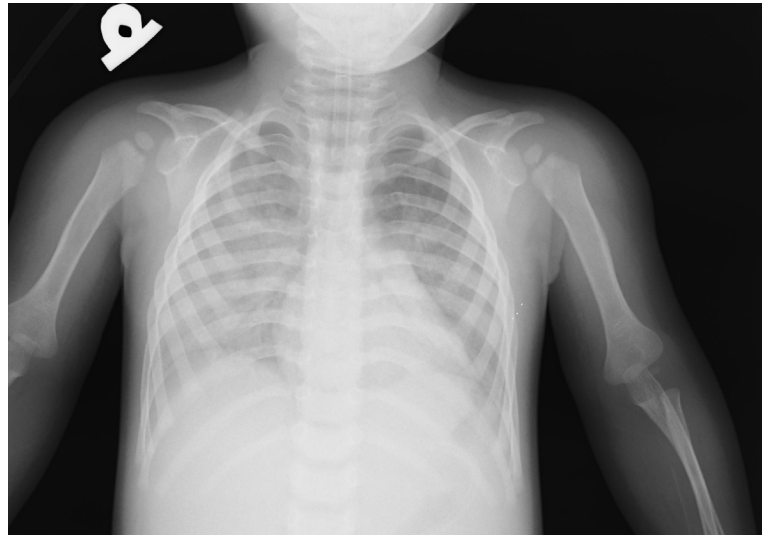


Fig. 2. X-ray was taken after intubation for checking position of the tube

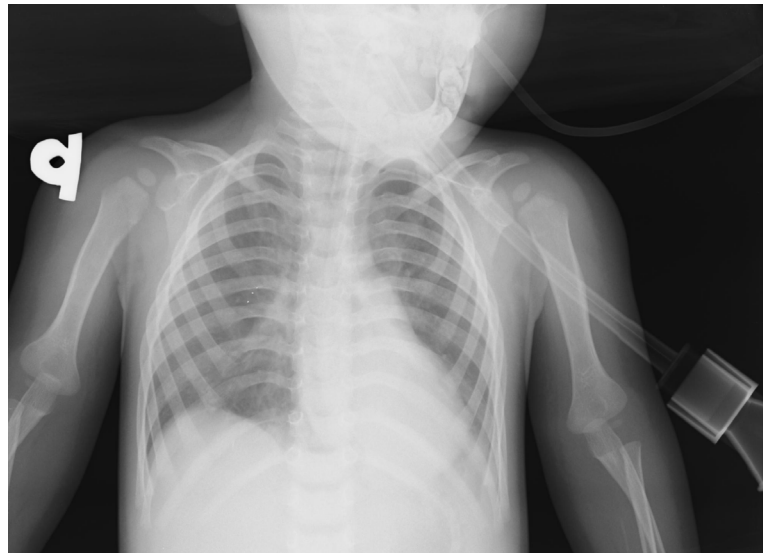

Fig. 3. X-ray was taken after bronchoscopy

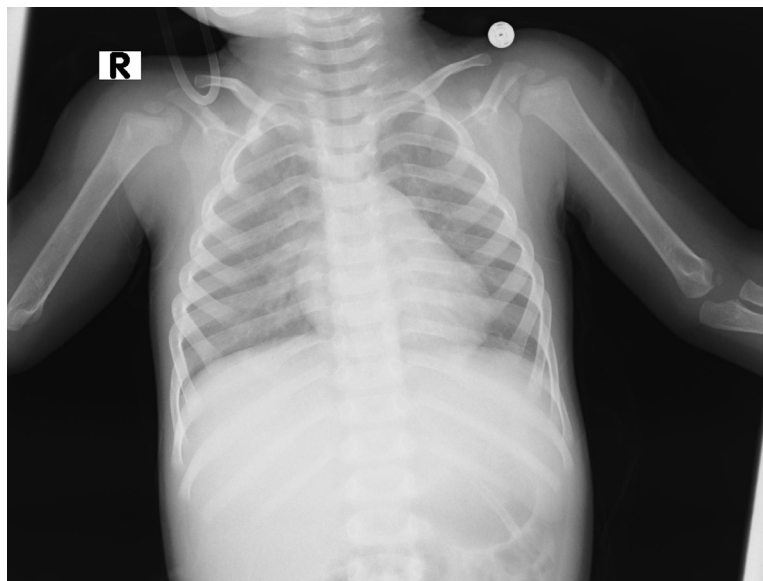


Fig. 4. X-ray was taken after recovery

during recovery. Continuous follow-up is essential to ensure complete resolution and to prevent possible complications. The chest radiography is an indicator for the presence of pulmonary disease, with a characteristic distribution of lung

aspiration, as well as for the progression or resolution of the process in time. The integration of clinical and radiological information is essential for an accurate diagnosis and an appropriate therapeutic approach in pneumonia.

### References

1. Bartlett JG. Aspiration pneumonia. In: Baum. G.L., Emanuel, W. Text 1989;85(1):155-61 book of pulmonary diseases. 5th ed. Vol. 1, Boston, Little, Brown and Company, 1993, pp.593-606.
2. Buonsenso D, De Rose C, Morello R, Lazzareschi I, Valentini P. Aspiration pneumonia in children with neurological disorders: a new indication for lung ultrasound? A case series. *J Ultrasound*. 2022;25(2):325-331. doi:10.1007/s40477-020-00520-4
3. Chandola S, Bhalla AS, Jana M, Naranje P, Vyas S. Pulmonary Aspiration Syndromes: An Imaging-based Review. *J Thorac Imaging*. 2025;40(4):e0821. Published 2025 Jul 1. doi:10.1097/RTI.0000000000000821
4. Chen X, Pereira N, Ciecieręga T, Graw-Panzer K, Maresh AM. Aerodigestive evaluation of pediatric patients with chronic aspiration. *Int J Pediatr Otorhinolaryngol*. 2024;182:112028. doi:10.1016/j.ijporl.2024.112028
5. Dop D, Gheonea C, Stănescu GL, et al. Aspiration pneumonia in an infant with neurological sequelae - case report. *Rom J Morphol Embryol*. 2015;56(3):1191-1194
6. Girard V, Bai AD. Aspiration pneumonia. *CMAJ*. 2023; 195 (41): E1417. doi:10.1503/cmaj.230628
7. Gropper MA, Miller RD, Eriksson LI, et al. Miller's Anesthesia, 2-Volume Set (9th Edition) – PDF. Elsevier; May 2, 2019
8. Imdad A, Wang AG, Adlakha V, et al. Laryngeal Penetration and Risk of Aspiration Pneumonia in Children with Dysphagia-A Systematic Review. *J Clin Med*. 2023; 12(12):4087. Published 2023 Jun 16. doi:10.3390/jcm12124087
9. Karim RM, Momin IA, Lalani II, et al. Aspiration pneumonia in pediatric age group: etiology, predisposing factors and clinical outcome. *J Pak Med Assoc*. 1999;49(4):105-108.
10. Komiya K, Rubin BK, Kadota JI, et al. Prognostic implications of aspiration pneumonia in patients with community

- acquired pneumonia: A systematic review with meta-analysis. *Sci Rep*. 2016;6:38097. Published 2016 Dec 7. doi:10.1038/srep38097
11. Mandell LA, Niederman MS. Aspiration pneumonia. *N Engl J Med* 2019;380:651-63
  12. Marik PE. Aspiration pneumonitis and aspiration pneumonia. *N Engl J Med* 2001; 344: 665-71
  13. de Oliveira GA, Pessanha LB, Guerra LF, Martins DL, Rondina RG, Silva JR. Aspiration pneumonia in children: an iconographic essay. *Radiol Bras*. 2015;48(6):391-395. doi:10.1590/0100-3984.2014.0007
  14. Parkash UB. Lungs in mixed connective tissue disease. *J Thorac Imaging*, 1992;7:55-61
  15. Petroianni A, Ceccarelli D, Conti V, Terzano C. Aspiration pneumonia. Pathophysiological aspects, prevention and management. A review. *Panminerva Med*. 2006; 48(4): 231-239.
  16. Plut D, Winant AJ, Mahomed N, et al. Unusual pediatric lung infections: imaging findings. *Pediatr Radiol*. 2024;54(4):516-529. doi:10.1007/s00247-023-05818-z
  17. Rashed, M.M., Hosseini, M.H., Beizae, B. et al. Imaging changes of oil aspiration over time in children: a case series. *Egypt J Bronchol* 17, 63 (2023). <https://doi.org/10.1186/s43168-023-00242-1>
  18. Rossi, C.S., da Silva, R.D., Ribeiro, M. et al. Risk Factors Associated to Aspiration Pneumonia in Adults and Elderly Patients: A Scoping Review. *Dysphagia* (2025). <https://doi.org/10.1007/s00455-025-10887-3>.
  19. Shabeera RP, MounikaV, Pneumonia and types & An Over view on aspiration pneumonia, *Int. J. of Pharm. Sci.*, 2024, Vol 2, Issue 1, 675-689. <https://doi.org/10.5281/zenodo.10570770>
  20. Salik I, Doherty TM. Mendelson Syndrome. In: *StatPearls. Treasure Island (FL): StatPearls Publishing; June 12, 2023.*
  21. Sanivarapu RR, Vaqar S, Gibson J. Aspiration Pneumonia. In: *StatPearls. Treasure Island (FL): StatPearls Publishing; March 20, 2024.* Sanivarapu RR, Vaqar S, Gibson J. Aspiration Pneumonia. In: *StatPearls. Treasure Island (FL): StatPearls Publishing; March 20, 2024*
  22. Son YG, Shin J, Ryu HG. Pneumonitis and pneumonia after aspiration. *J Dent Anesth Pain Med*. 2017; 17(1): 1-12. doi:10.17245/jdapm.2017.17.1.1
  23. Tutor JD, Gosa MM. Dysphagia and aspiration in children. *Pediatr Pulmonol*, 2012, 47(4):321–337
  24. Weir K, McMahon S, Barry L, Ware R, Masters IB, Chang AB. Oropharyngeal aspiration and pneumonia in children. *Pediatr Pulmonol*, 2007, 42(11):1024–1031

**РЕЗЮМЕ****АСПИРАЦИОННАЯ ПНЕВМОНИЯ  
У ПЕДИАТРИЧЕСКИХ ПАЦИЕНТОВ:  
РЕНТГЕНОЛОГИЧЕСКИЕ ОСОБЕННОСТИ  
(клинический случай)**Стуруа Д.Г.,<sup>1</sup> Джоджуа Н.Д.,<sup>2</sup> Дундуа,Т.Т.<sup>3</sup>;

<sup>1</sup>Детская центральная больница им. М. Иашвили; Высшая медицинская школа АИЕТИ им. Д. Твилдиани, Тбилиси, Грузия; <sup>2</sup>Детская центральная больница им. М. Иашвили,Тбилиси, Грузия; <sup>3</sup>Университет Грузии; Клиника Кортекс, Тбилиси, Грузия.

Аспирационная пневмония - серьезная патология, имеющая особое клиническое значение у детей. Аспирация развивается при попадании содержимого желудка, пищевой массы или другого инородного тела в дыхательные пути из-за нарушения функции защитных механизмов организма, что значительно повышает риск развития инфекции. У педиатрических пациентов аспирация может быть вызвана незрелостью координации глотания, неврологическими нарушениями, аномалиями развития, гастроэзофагеальным рефлюксом или врождёнными аномалиями, такими как трахеозофагеальная фистула. В данной статье представлен клинический случай аспирационной пневмонии у пациента детского возраста. Проанализированы и описаны данные рентгенографии грудной клетки. На рентгенограмме были выявлены перихилярные инфильтраты, перибронхиальное утолщение, сегментарная коуплотненность и ателектаз. У детей также наблюдалась гиперпневматизация легочной ткани и признаки мозаичной вентиляции, что связано с воспалительным процессом дыхательных путей. Поражение было более локализовано в Рентгенография грудной клетки играет важную роль в диагностике аспирационной пневмонии, особенно в раннем детском возрасте. Это основной метод оценки течения заболевания. Своевременная диагностика и лечение значительно снижают риск осложнений и хронического поражения легких.

**Ключевые слова:** Аспирационная пневмония, рентгенография грудной клетки, радиология, диагностика у детей.

**რეზიუმე****რენტგენოლოგიური მახასიათებლები ასპირაციული პნევმონიის მქონე ბავშვებში (კლინიკური შემთხვევა)**სტურუა დ.გ.<sup>1</sup>, ჯოჯუა ნ.ჯ.<sup>2</sup>, დუნდუა თ.თ.<sup>3</sup>

<sup>1</sup>მ. იაშვილის სახელობის ბავშვთა ცენტრალური საავადმყოფო; დ. ტვილდიანის სახელობის უმაღლესი სამედიცინო სკოლა აიეტი, თბილისი, საქართველო. <sup>2</sup>მ. იაშვილის სახელობის ბავშვთა ცენტრალური საავადმყოფო, თბილისი, საქართველო. <sup>3</sup>საქართველოს უნივერსიტეტი; კლინიკა კორტექსი, თბილისი, საქართველო

ასპირაციული პნევმონია წარმოადგენს სერიოზულ პათოლოგიას, რომელსაც განსაკუთრებული კლინიკური მნიშვნელობა აქვს პედიატრიულ პაციენტებში. ასპირაცია ვითარდება მაშინ, როდესაც სასუნთქ გზებში ხვდება კუჭის შიგთავსი, საკვები მასა ან სხვა უცხო სხეული ორგანიზმის დამცავი მექანიზმების დისფუნქციის გამო, რაც მნიშვნელოვნად ზრდის ინფექციის განვითარების რისკს.

ამ სტატიაში წარმოდგენილია პედიატრიული ასაკის პაციენტში ასპირაციული პნევმონიის კლინიკური შემთხვევა. შეფასებული და აღწერილია გულმკერდის რენტგენოლოგიური მონაცემები.

რენტგენოლოგიური კვლევით გამოვლინდა პერიჰილარული ინფილტრატები, პერიბრონქიალური გასქელება, სეგმენტური კოსოლიდაცია და ატელექტაზი. ასევე აღინიშნებოდა ფილტვის ქსოვილის ჰიპერპნევმატიზაცია და მოზაიკური ვენტილაციის ნიშნები, რაც სასუნთქი გზების ანთებით პროცესთან არის დაკავშირებული. დაზიანება უფრო მეტად ლოკალიზებული იყო მარჯვენა ფილტვში, განსაკუთრებით მარჯვენა ქვედა წილში.

გულმკერდის რენტგენოგრაფიული კვლევა მნიშვნელოვან როლს ასრულებს ასპირაციული პნევმონიის დიაგნოსტიკაში განსაკუთრებით ადრეული ასაკის ბავშვებში. იგი წარმოადგენს დაავადების შეფასების მთავარ მეთოდს. დროული დიაგნოზი და მკურნალობა მნიშვნელოვნად ამცირებს გართულებებისა და ფილტვის ქრონიკული დაზიანების რისკს.

**საკვანძო სიტყვები:** ასპირაციული პნევმონია, გულმკერდის ღრუს ორგანოების რენტგენოგრაფია, რადიოლოგია, დიაგნოზი ბავშვებში.